

Iron binding proteins in gallbladder carcinomas. An immunocytochemical investigation

G. Tuccari¹, R. Rossiello² and G. Barresi¹

¹Department of Human Pathology, University of Messina, Messina and

²Institute of Pathological Anatomy, University of Naples, Naples, Italy

Summary. By immunohistochemistry, the presence of major iron-binding proteins (lactoferrin, transferrin, ferritin) has been investigated in adenocarcinomas (27 cases), adenosquamous carcinoma (1 case), undifferentiated sarcomatoid carcinoma (1 case) and mucinous adenocarcinomas (3 cases) of the gallbladder; 10 samples of chronic lithyasic cholecystitis, 4 adenomyomas and 6 tubulo-villous adenomas have also been studied.

In a variable share of adenocarcinomas, a positive immunoreactivity for iron-binding antisera was encountered in the cytoplasm, while tubulo-villous adenomas, adenomyomas and the normal epithelium of the gallbladder were generally unreactive. In carcinomatous lesions, the staining intensity was variable between different cases or individual tumour cells.

The production of these iron-binding proteins in the gallbladder carcinoma in itself could be related to a greater availability of iron for metabolic processes in the neoplastic cell; alternatively, the cytoplasmic localization of these substances in carcinomatous elements may be a consequence of a defective or impaired function of iron-binding receptors with a modified degree of transmembranous iron transfer.

Key words: Immunohistochemistry, Lactoferrin, Transferrin, Ferritin, Gallbladder carcinoma

Introduction

Lactoferrin (Lf), transferrin (Tf) and ferritin (Ft) are the three major iron-binding proteins detected by radioimmunological and immunoenzymatic procedures in many biological fluids as well as in human fetal and adult tissues (Masson et al., 1966; De Vet and Van Gool, 1974; Mason and Taylor, 1978; Brock, 1980; Reitamo et al., 1980; Korsrud and Brandtzaeg, 1982). By immunohistochemistry, the distribution of these iron-binding

proteins has been extensively investigated in normal human tissues such as stomach, kidney, lung, pancreas, liver and bone marrow (Mason and Taylor, 1978).

In neoplastic conditions, the presence of Lf, Tf and Ft has been studied in breast carcinomas (Rossiello et al., 1984), in thyroid tumours (Barresi and Tuccari, 1987) and in colorectal adenomas and carcinomas (Tuccari et al., 1992); moreover, Lf has been demonstrated in neoplasias of the parotid (Caselitz et al., 1981), prostate (Barresi and Tuccari, 1984), kidney (Loughlin et al., 1987) and stomach (Tuccari et al., 1989), whereas Tf is widely distributed in many different malignant soft tissue tumours (Otto et al., 1987) and Ft has been reported in embryonal carcinoma (Wahren et al., 1977), in carcinoma in situ of the testes (Jacobson et al., 1980) and in hepatocellular carcinoma (Imoto et al., 1985). In the above-mentioned neoplastic lesions, the origin of iron-binding proteins has not been elucidated, but their autoctone production by neoplastic elements in order to have a greater availability of iron for the cellular turnover has been hypothesized (Birgens, 1984; Weinberg, 1984; Barresi and Tuccari, 1987; Tuccari et al., 1992); however, the Lf production by neoplastic elements has been claimed to explain low iron levels in renal carcinomas (Loughlin et al., 1987), even if a role for Lf as a mediator of neoplastic anaemia has been excluded in carcinomas of the stomach and colon rectum (Tuccari et al., 1989, 1992).

On the light of these reports, we have thought it to be of interest to investigate the immunohistochemical distribution of Lf, Tf and Ft in carcinomas of the gallbladder, which in normal conditions is unreactive for these iron-binding proteins in the mucosa, even if Lf has been biochemically documented in bile products (Masson et al., 1966; De Vet and Van Gool, 1974).

Materials and methods

Surgical specimens of gallbladder collected in the period 1992-1995 were obtained from 52 patients. Using the criteria of WHO (1992), the histopathological diagnosis was: chronic lithyasic cholecystitis (10 cases);

Iron-binding proteins in gallbladder carcinomas

adenomyoma (4 cases); tubulo-villous adenoma (6 cases); adenocarcinoma (27 cases); adenosquamous carcinoma (1 case); undifferentiated sarcomatoid carcinoma (1 case); mucinous adenocarcinoma (3 cases). The staging of 32 carcinomas (M:F/9:23; age range 32-76 yrs, mean 57.53), performed according to the criteria of Nevin et al. (1976), showed 8 cases in stage I, 13 cases in stage II, 6 cases in stage III, and 5 cases in stage IV. With reference to the grading, 4 cases were G1, 12 cases were G2, 10 cases were G3 and 6 cases were G4.

All specimens, fixed in 10% neutral formalin for 12-24 hours at room temperature, were embedded in paraffin at 55 °C and cut into thin sections by routine histological procedure. For the immunohistochemical study, 4-5 µm-thick sections were treated in a moist chamber for 30 min each time: 1) with 0.1% H₂O₂ in methanol to block the intrinsic peroxidase activity; 2) with normal sheep serum to prevent unspecific adherence of serum proteins; 3) with rabbit anti-human Lf, Tf and Ft (w.d. 1:300) (purchased from Dako, Copenhagen, Denmark); 4) with sheep anti-rabbit immunoglobulin antiserum (Behring Institute; w.d.

1:25); and 5) with rabbit anti-horseradish PAP complexes (Dako; w.d. 1:25). For the demonstration of peroxidase activity the sections were incubated in darkness (Weir et al., 1974) for 10 min with fresh 3-3' diaminobenzidine tetrahydrochloride (100 mg in 200 ml 0.03% hydrogen peroxide in PBS) (Sigma Chemical Co., St. Louis, MO, USA).

The assessment of immunostained sections was performed on a consensus basis by 2 pathologists (G.T. and G.B.), using a double-headed microscope; the staining intensity was graded as: + (weak), ++ (moderate), +++ (strong). The percentage of stained cells was graded as: 0 (no staining); 1 (>0 to 5%); 2 (>5 to 50%); 3 (>50%); and a good correlation and reproducibility were obtained by the two observers. Statistical analysis was performed using χ^2 test with Yate's correction.

To test the specificity of Lf, Tf and Ft immunostainings, each specific antiserum was replaced by either phosphate-buffered saline, normal rabbit serum or was absorbed with excess of purified human Lf, Tf and Ft from human liver and spleen (Sigma Chemical Co.): the results obtained were negative.

Table 1. Clinico-pathological and immunohistochemical data of 32 gallbladder carcinomas studied.

CASE	SEX	AGE	HISTOLOGICAL TYPE	GRADE	STAGE	LACTOFERRIN		TRANSFERRIN		FERRITIN	
						Staining intensity	Staining score	Staining intensity	Staining score	Staining intensity	Staining score
1	F	66	ACpap	1	I	++	2	+ / ++	1	+	1
2	M	32	ACmuc	1	I	-	0	-	0	-	0
3	M	55	AC	1	I	-	0	-	0	-	0
4	F	37	ACpap	1	I	++	1	++	1	-	0
5	F	68	AC	2	I	-	0	+	3	+ / -	1
6	F	33	AC	2	I	++	0	+ / -	2	-	0
7	F	48	ACpap	2	I	+	1	-	0	-	0
8	F	62	AC	2	I	-	1	-	0	-	0
9	M	68	AC	2	II	-	0	+ / -	1	-	0
10	M	71	AC	2	II	++	1	-	0	-	0
11	M	44	AC	2	II	++	3	++	1	+	2
12	F	51	AC	2	II	-	0	+	2	+	2
13	F	52	AC	2	II	-	0	+	1	-	0
14	M	60	AC	2	II	-	0	+	1	-	0
15	F	74	AC	2	II	-	0	++	1	-	0
16	F	60	AC	3	II	++	2	++	2	++	1
17	F	53	ACpap	3	II	+++	2	+ / ++	1	-	0
18	M	76	AC	3	II	+	1	+ / -	2	-	0
19	M	76	AC	3	II	+ / -	1	+	2	-	0
20	F	62	AC	3	II	-	0	-	0	-	0
21	F	49	AC	4	II	-	0	-	0	-	0
22	F	62	AC	2	III	+	2	-	1	+ / -	1
23	F	71	ACmuc	3	III	-	0	++	3	-	0
24	F	52	ACmuc	3	III	-	0	-	0	-	0
25	F	53	AC	3	III	-	1	+	1	-	0
26	F	60	AC	4	III	-	0	+ / -	1	-	0
27	F	50	AC	4	IV	++	2	+	1	-	0
28	M	57	AC	3	IV	+ / -	1	+ / -	1	-	0
29	F	54	ASC	3	IV	+ / -	2	+ / -	1	-	0
30	F	62	AC	4	IV	-	0	+	2	++	1
31	F	69	UC	4	IV	+	2	-	0	-	0
32	F	54	AC	4	IV	-	0	-	0	-	0

AC: adenocarcinoma; ACpap: papillary adenocarcinoma; ACmuc: mucinous adenocarcinoma; ASC: adenosquamous carcinoma; UC: undifferentiated carcinoma.

Results

The clinico-pathological and immunohistochemical

data concerning gallbladder carcinomatous lesions are summarized in Table 1.

In gallbladder carcinomas, a positive immunoreactivity was encountered in 15/32 cases for Lf, 18/32

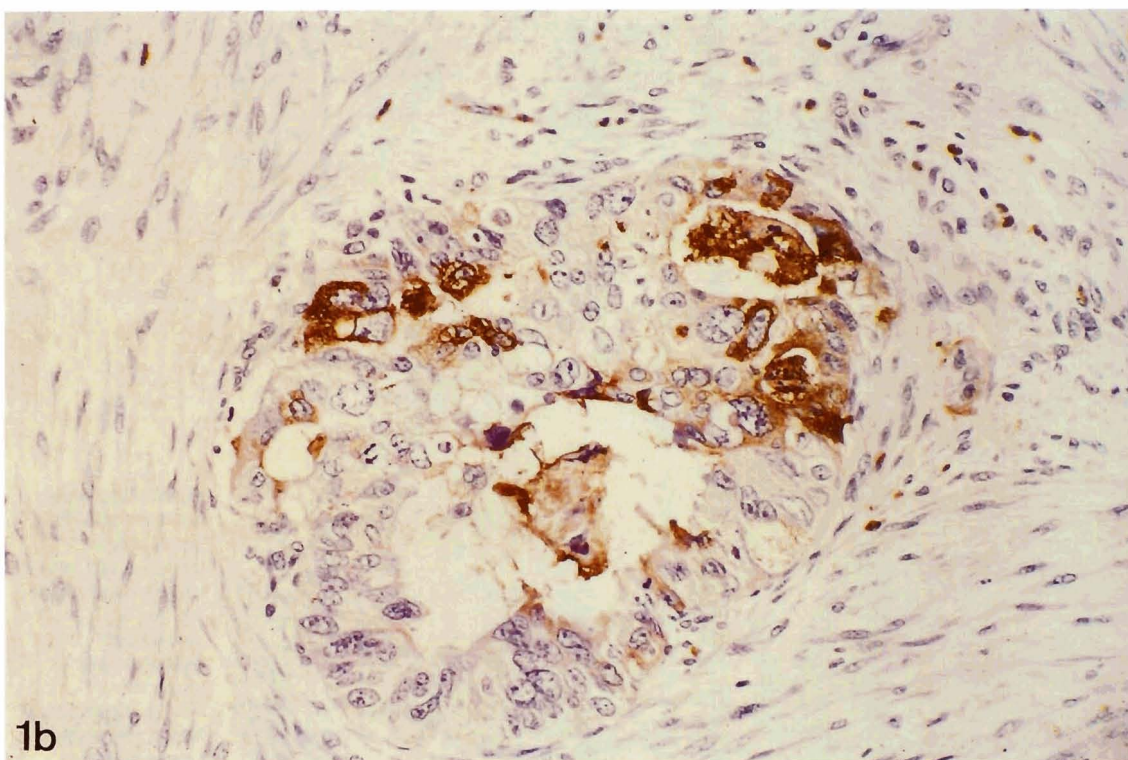
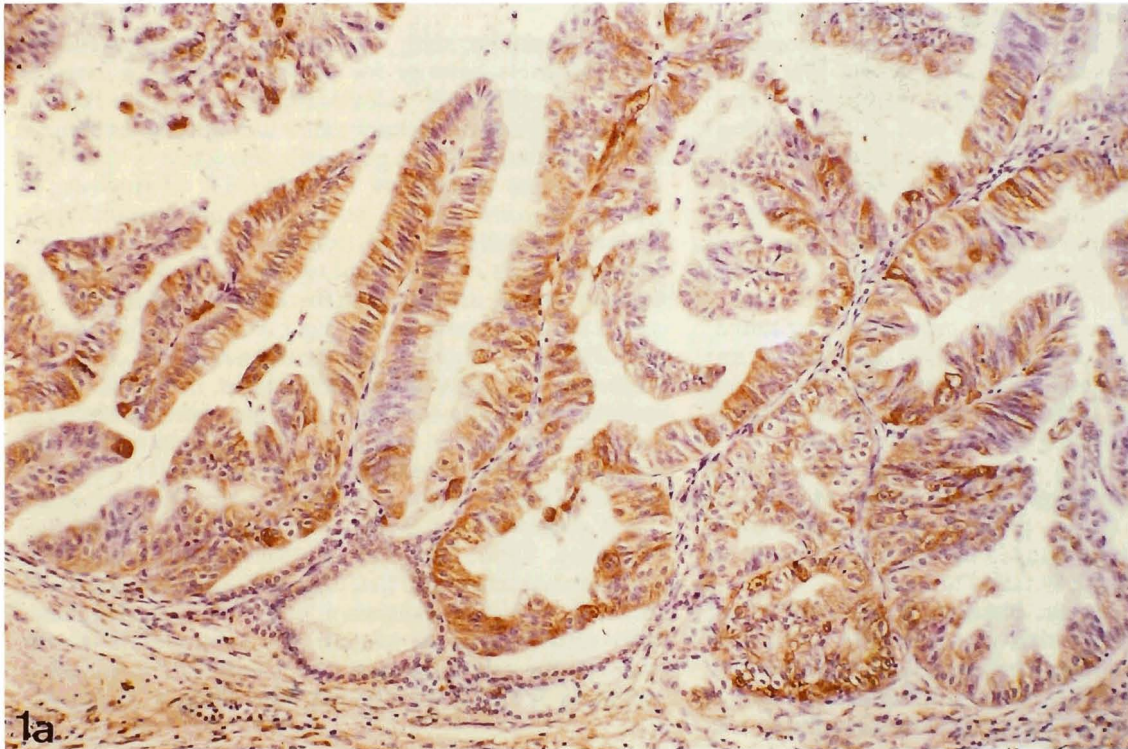


Fig. 1. Gallbladder carcinoma. **a.** An evident diffuse cytoplasmic immunopositivity is encountered in papillary areas. Immunoperoxidase anti-Lf, Mayer's haemalum counterstain. x 160. **b.** Some neoplastic elements are strongly stained with Ft. Immunoperoxidase, Mayer's haemalum counterstain. x 330

for Tf, and 10/32 for Ft; the immunolocalization was specifically cytoplasmic, mainly represented in neoplastic papillary or glandular areas (Fig. 1a,b), while squamous or sarcomatoid component of tumours were negative for iron-binding proteins. In connective stroma, particularly in areas surrounding solid neoplastic nests, a frequent positivity for Ft was detected, mainly localized in the cytoplasm of spindle-shaped elements. Mucinous adenocarcinomas were constantly unreactive. The immunohistochemical reactivity as well as the staining intensity showed evident differences in the context of the same tumour. In addition, the immunopositivity was independent from the macroscopic neoplastic appearance and the tumour stage; no relationship was found between the carcinomatous grading and the immunoreaction.

Tubulo-villous adenomas were only slightly reactive with all iron-binding proteins. In villous apical areas, an intense not homogeneous cytoplasmic positivity was evident only for Tf, although strongly positive and slightly positive cells were found in direct contact.

Fundic adenomyomas were generally unreactive, although a cytoplasmic reactivity with Lf and Tf antisera was appreciable in some epithelial components of a single case (Fig. 2); intermingled muscular bundles were always unstained (Fig. 2). Ft failed to react.

The gallbladder mucosa obtained from samples of chronic lithyasic cholecystitis was generally unstained for Lf and Ft, while a focal occasional slight positivity was encountered with Tf antiserum. Inflammatory cells, variously represented in the specimens, exhibited an

evident immunoreactivity with all antisera; in particular, an intense cytoplasmic positivity for Lf was noted in polymorphonuclear neutrophils.

Discussion

In the present study, we have documented an evident cytoplasmic reactivity for Lf, Tf and Ft in a variable share of gallbladder adenocarcinomas, while tubulo-villous adenomas, adenomyomas and normal epithelium of the gallbladder were generally unreactive or showed a focal slight positivity only for Tf. Moreover, in carcinomatous lesions, an appreciable variability in staining intensity for these iron-binding proteins between different cases or individual tumour cells was observed in our cases, although differentiated glandular or papillary areas showed a stronger reaction in comparison to solid ones, mucinous adenocarcinomas and some less differentiated cases. On the other hand, the variability in cellular transferrin expression has also been observed in other malignancies and it has been explained by the influence of a multitude of factors, such as the iron need and availability or the state of activation (Gatter et al., 1983; Bomford and Munro, 1985; Hunt, 1986; Walker and Day, 1986; Wrba et al, 1986); therefore, if the immunohistochemical heterogeneity encountered by us in the iron-binding expression of gallbladder carcinomas may reflect different tumour cell subpopulations, the stage in the cell cycle and/or metabolic abnormalities is presently not fully ascertained. Nevertheless, taking into

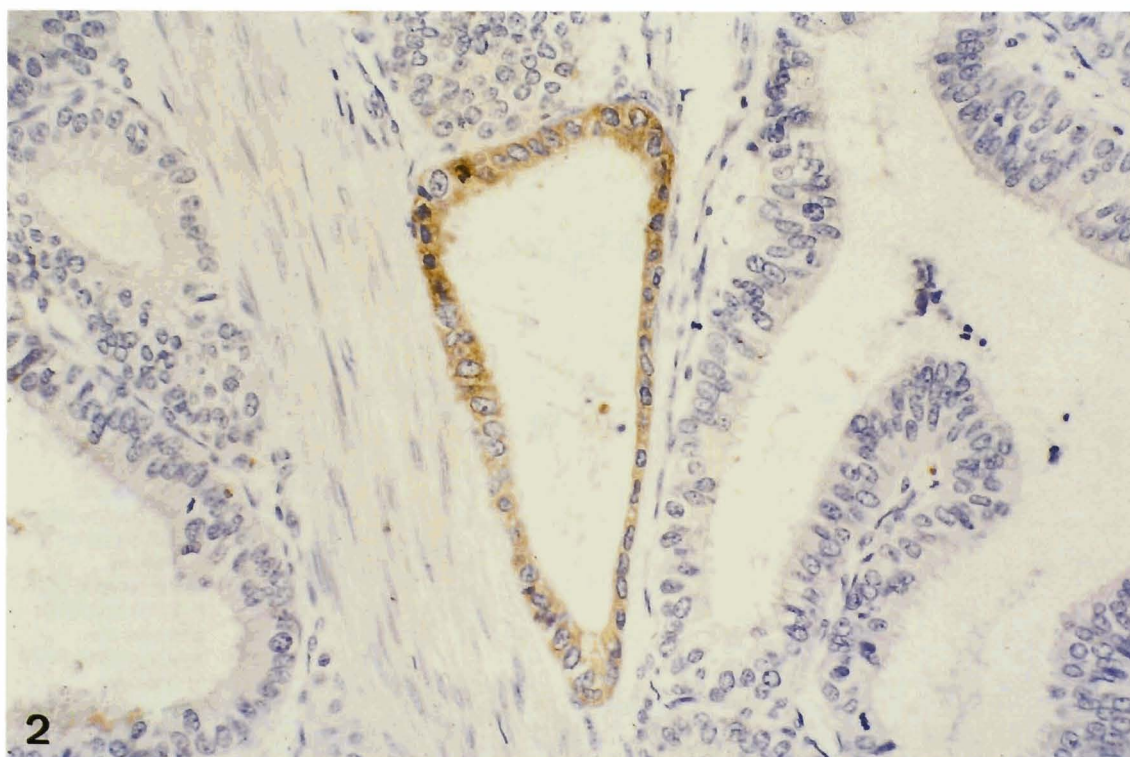


Fig. 2. Gallbladder adenomyoma. Tf stains only a glandular unit, while muscle bundles and the rest of gallbladder epithelium are unreactive. Immunoperoxidase, Mayer's haemalum counterstain. x 330

account our data concerning the Lf and Tf distribution in better differentiated gallbladder carcinomas, it may be hypothesized a role as markers of glandular differentiation for the two above-mentioned iron-binding proteins; however, this suggestion has been pointed out in previous immunohistochemical investigations performed with the same antisera in other malignancies, such as tumours of the parotid, prostate, breast and thyroid (Caselitz et al., 1981; Barresi and Tuccari, 1984; Charpin et al., 1985; Tuccari and Barresi, 1985; Cabaret et al., 1992).

The origin of iron-binding proteins in neoplasias has not yet been completely elucidated. Although we cannot exclude the possibility that these proteins might be involved in the defense system against tumours, it is probable that the presence of these substances (e.g. Lf, Tf) in the neoplastic cells of some gallbladder carcinomas is related to the production of the proteins in the tumour in itself. The intense staining for Lf and Tf, as revealed by the immunoperoxidase technique, is an argument for the production by the tumour tissue itself, although this interpretation should be controlled by methods other than morphological analysis. Therefore, we retain that adenocarcinomatous elements of gallbladder may produce Lf and Tf in order to have a greater availability of iron for their turnover. However, it is well known that Tf has a high affinity for iron, and still greater is the capability of Lf to bind iron, exceeding that of Tf by a factor of 260 (Birgens, 1984). Moreover, iron is an essential nutrient for cells that are dividing rapidly such as tumour cells (Weinberg, 1984); in addition, iron is crucial for various metabolic processes in the cell, such as oxidative phosphorylation and RNA and DNA synthesis (Bacon and Tavill, 1984; Bomford and Munro, 1985; Shoji and Ozawa, 1986). On the other hand, in order to explain the presence of Lf and Tf in neoplastic cells of some gallbladder carcinomas, an alternative hypothesis should be considered since the accumulation of these iron-binding proteins may be a consequence of defective or functionally impaired Lf and Tf receptors. In fact, all growing cells express surface transferrin receptors that bind ferrotransferrin, which is then subjected to receptor-mediated endocytosis (Iacopetta et al., 1983); in addition specific Lf binding sites, different from Tf receptors, have been shown in a human adenocarcinoma cell line HT 29 (Roiron et al., 1989). According to this hypothesis, the cytoplasmic localization of Lf and Tf does not reflect an intracellular synthesis of iron-binding proteins by neoplastic elements, but the degree of transmembranous iron transfer.

Finally, although the use of serum level of Ft has been previously utilized as a tool for the diagnosis of malignancies (Bullock et al., 1980; Nakano et al., 1984), the presence of Ft in human tissues and tumours has been related to its detoxifying and storing iron function (Walters et al., 1973; Imoto et al., 1985). Moreover, by immunohistochemistry, it has been demonstrated that some well differentiated hepatocellular carcinomas,

according to Edmondson's grade, preferentially produce and/or retain Ft rather than the poorly differentiated ones (Imoto et al., 1985). Interestingly, this finding is similar to that observed in our cases of gallbladder carcinomas, where an intense positivity was encountered only in well differentiated cases with glandular or papillary appearance.

References

- Bacon B.R. and Tavill A.S. (1984). Role of the liver in normal iron metabolism. *Sem. Liver Dis.* 4, 181-192.
- Barresi G. and Tuccari G. (1984). Lactoferrin in benign hypertrophy and carcinomas of the prostatic gland. *Virchows Arch. (A)* 403, 59-66.
- Barresi G. and Tuccari G. (1987). Iron-binding proteins in thyroid tumours. An immunocytochemical study. *Pathol. Res. Pract.* 182, 344-351.
- Birgens H.S. (1984). The biological significance of lactoferrin in haematology. *Scand. J. Hematol.* 33, 225-230.
- Bomford A.B. and Munro H. (1985). Transferrin and its receptor: their role in cell function. *Hepatology* 5, 870-875.
- Brock J.H. (1980). Lactoferrin in human milk: its role in iron absorption and protection against enteric infection in the newborn infant. *Arch. Dis. Child.* 55, 417-421.
- Bullock S., Bomford A. and Williams R. (1980). A biochemical comparison of normal human liver and hepatocellular carcinoma ferritins. *Biochem. J.* 85, 639-645.
- Cabaret V., Vilain M.O., Delobelle-Deroide A. and Vanseymortier L. (1992). Détection immunohistochemique de la céruloplasmine et de la lactoferrine sur une série de 59 tumeurs thyroïdiennes. *Ann. Pathol.* 12, 347-352.
- Caselitz J., Jaup T., and Seifert G. (1981). Lactoferrin and lysozyme in carcinomas of the parotid gland. *Virchows Arch. (A)* 394, 61-73.
- Charpin C., Lachard A., Pourreau-Schneider N., Jacquemier J., Lavaut M.N., Andonian C., Martin P.M. and Toga M. (1985). Localization of lactoferrin and nonspecific cross-reacting antigen in human breast carcinomas. *Cancer* 55, 2612-2617.
- De Vet B.J.C.M. and Van Gool J. (1974). Lactoferrin and iron absorption in the small intestine. *Acta Med. Scand.* 196, 393-402.
- Gatter K.C., Brown G., Trowbridge I.S., Woolston R.E. and Mason D.Y. (1983). Transferrin receptors in human tissues: their distribution and possible clinical relevance. *J. Clin. Pathol.* 36, 539-545.
- Hunt R.C. (1986). Endocytosis and control of expression of transferrin receptor. *Dev. Comp. Immunol.* 10, 273-277.
- Iacopetta B.J., Morgan E.H., Yeoh G.C.T. (1983). Receptor-mediated endocytosis of transferrin by developing erythroid cells from the fetal rat liver. *J. Histochem. Cytochem.* 31, 336-344.
- Imoto M., Nishimura D., Fukuda Y., Sugiyama K., Kumada T. and Nakano S. (1985). Immunohistochemical detection of fetoprotein, carcinoembryonic antigen, and ferritin in formalin-paraffin sections from hepatocellular carcinoma. *Am. J. Gastroenterol.* 80, 902-906.
- Jacobson G.K., Jacobson G. and Clausen P.P. (1980). Ferritin as a possible marker protein of carcinoma in situ of the testis. *Lancet* II, 533-534.
- Korsrud F.R. and Brandtzaeg P. (1982). Characterization of epithelial elements in human major salivary glands by functional markers: localization of amylase, lactoferrin, lysozyme, secretory component, and secretory immunoglobulins by paired immunofluorescence staining. *J. Histochem. Cytochem.* 30, 657-666.

Iron-binding proteins in gallbladder carcinomas

- Loughlin K.R., Gittes R.F. and Partridge D. (1987). The relationship of lactoferrin to the anemia of renal carcinoma. *Cancer* 59, 566-571.
- Mason D.Y. and Taylor C.R. (1978). Distribution of transferrin, ferritin and lactoferrin in human tissues. *J. Clin. Pathol.* 31, 316-327.
- Masson P.L., Heremans J.F. and Dire C. H. (1966). An iron-binding protein common to many external secretions. *Clin. Chim. Acta* 14, 735-739.
- Nakano S., Kumada T. and Sugiyama K. (1984). Clinical significance of serum ferritin determination for hepatocellular carcinoma. *Am. J. Gastroenterol.* 79, 623-627.
- Nevin J.E., Moran T.J., Kay S. and King R. (1976). Carcinoma of the gallbladder. *Cancer* 37, 141-148.
- Otto H.F., Berndt R. and Schwenchheimer K. (1987). Mesenchymal tumor markers: special proteins and enzymes. In: *Morphological tumor markers*. Seifert G. (ed). Springer-Verlag, Heidelberg, pp 179.
- Reitamo S., Kontinnen Y.T. and Segerber-Kontinnen M. (1980). Distribution of lactoferrin in human salivary glands. *Histochemistry* 66, 285-291.
- Roiron D., Amouric M., Marvaldi J. and Figarella C. (1989). Lactoferrin-binding sites at the surface of HT29-D4 cells. *Eur. J. Biochem.* 186, 367-373.
- Rossiello R., Carriero M.V. and Giordano G.G. (1984). Distribution of ferritin, transferrin and lactoferrin in breast carcinoma tissue. *J. Clin. Pathol.* 37, 51-55.
- Shoji A. and Ozawa E. (1986). Necessity of transferrin for RNA synthesis in chick myotubes. *J. Cell Physiol.* 127, 349-356.
- Tuccari G. and Barresi G. (1985). Immunohistochemical demonstration of lactoferrin in follicular adenomas and thyroid carcinomas. *Virchows Arch. (A)* 406, 67-74.
- Tuccari G., Barresi G., Arena F. and Inferrera C. (1989). Immunocytochemical detection of lactoferrin in human gastric carcinomas and adenomas. *Arch. Pathol. Lab. Med.* 113, 912-916.
- Tuccari G., Rizzo A., Crisafulli C. and Barresi G. (1992). Iron-binding proteins in human colorectal adenomas and carcinomas: an immunocytochemical investigation. *Histol. Histopathol.* 7, 543-547.
- Wahren B., Alpert E. and Esposti P. (1977). Multiple antigens marker substances in germinal tumours of the testis. *J. Natl. Cancer Inst.* 58, 489-495.
- Walker R.A. and Day S.J. (1986). Transferrin receptor expression in non-malignant and malignant human breast tissue. *J. Pathol.* 148, 217-224.
- Walters C.O., Miller F.M. and Worwood M. (1973). Serum ferritin concentration and iron storage in normal subjects. *J. Clin. Pathol.* 26, 770-772.
- Weinberg E.D. (1984). Iron withholding: a defense against infection and neoplasia. *Physiol. Rev.* 64, 65-102.
- Weir E.E., Pretlow T.G. and Pitts A. (1974). A more sensitive and specific histochemical peroxidase for the localization of cellular antigen by the enzyme-antibody conjugate method. *J. Histochem. Cytochem.* 22, 1135-1140.
- Wrba F., Ritzinger E., Reiner A. and Holzner J.H. (1986). Transferrin receptor expression in breast carcinoma and its possible relationship to prognosis. *Virchows Arch. (A)* 410, 69-73.

Accepted January 7, 1997